



# Guide To Degenerative & Atraumatic Meniscal Tears



## DID YOU KNOW?

### ATRAUMATIC MENISCAL TEARS ARE COMMON ON MRI

For example, 25 per cent of 50-year-olds will have a meniscal lesion on MRI, while 45 per cent of 70-year-olds will have a meniscal lesion on MRI. Up to 95 per cent of patients with osteoarthritis will have a meniscal tear.

### SOME MENISCAL TEARS ARE REPAIRABLE

The outer third of the meniscus and the meniscal root have a blood supply. If the tear is confined to this location, it can be sutured back together.

### ATRAUMATIC KNEE PAIN IS OFTEN NOT DUE TO A MENISCAL TEAR

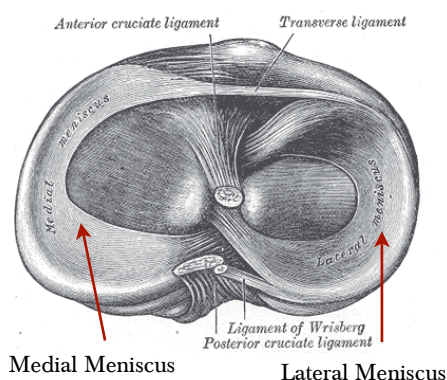
Usually the pain is due to co-existing osteoarthritis and bone bruising.

### ATRAUMATIC MENISCAL TEARS ARE TYPICALLY PART OF THE OSTEOARTHRITIS PROCESS

Pain, swelling and stiffness are common in osteoarthritis and are usually not due to the meniscal lesion seen on MRI.

### FOR MORE INFORMATION

Visit : <https://www.kneesociety.org.au/resources/aks-arthroscopy-position-statement.pdf>



**Most degenerative or atraumatic meniscal tears can be managed successfully without surgery, and although arthroscopic meniscectomy (meniscal trimming) remains a commonly performed procedure, recent evidence has allowed orthopaedic surgeons to narrow the indications for this type of surgery.**

Atraumatic meniscal tears typically develop slowly in middle aged and older patients, typically as part of developing osteoarthritis. These tears are often seen on MRIs, and occur more frequently as patients age.

### Caution must be taken in assessing atraumatic meniscal tears on MRI in middle aged or older patients.

Patients with repairable tears or obstructive (locked) symptoms may warrant early surgery; however, most patients do not benefit from it.

## Investigations

**History and examination** are vital to confirm the site of knee pain and to exclude other sources such as the hip or tumours.

**Weight-bearing X-rays** should be the first-line investigation (AP standing,

Lateral, Skyline and Rosenberg views).

**MRI** is a second-line test if the history, examination and X-rays are inconclusive.

**CT and US** have rare and tertiary roles in investigation.

## Management:

**1 Pain relief such as NSAIDs.** The benefits of paracetamol in isolation remain marginal. Opiates are best avoided, especially for chronic pain.

**2 Activity modification** to low-impact activity such as bike riding.

**3 Quads-strengthening** exercises and muscle strengthening.

**4 BMI Reduction** in overweight patients.

**5 Consider braces** in those who undertake moderate-impact activity.

**6 Injectable therapy** such as PRP and hyaluronic acid could be considered; however, the cost-benefits remain unclear. Corticosteroids can damage the joint and their benefit is mild, hence they should be used sparingly and only in acute settings. Stem cells do not benefit patients.

**7 Specialist review** is recommended if the patient fails to improve or the diagnosis remains uncertain.

